

Figure 6.1 Connective tissue wrappings of skeletal muscle.

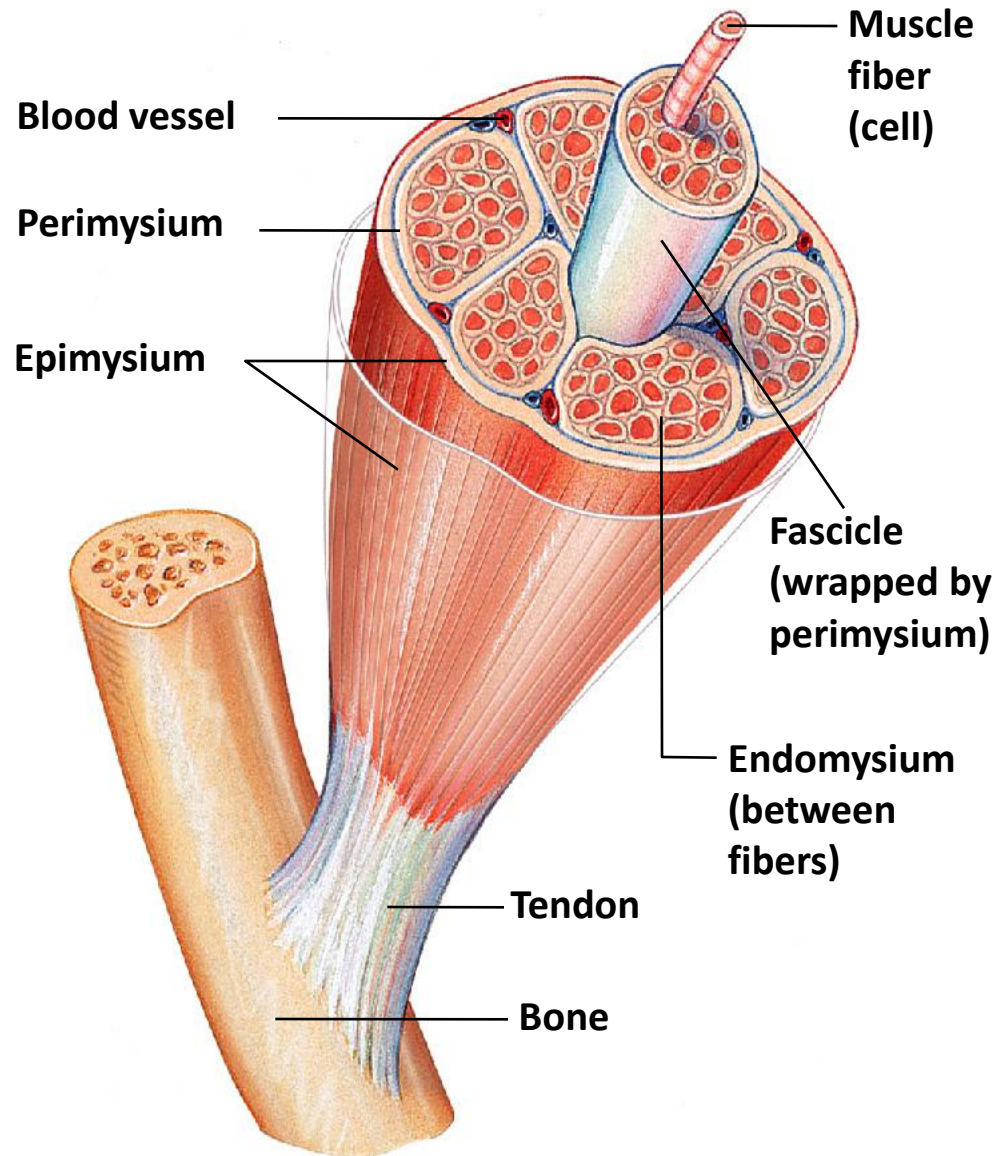


Figure 6.15 Superficial muscles of the face and neck.

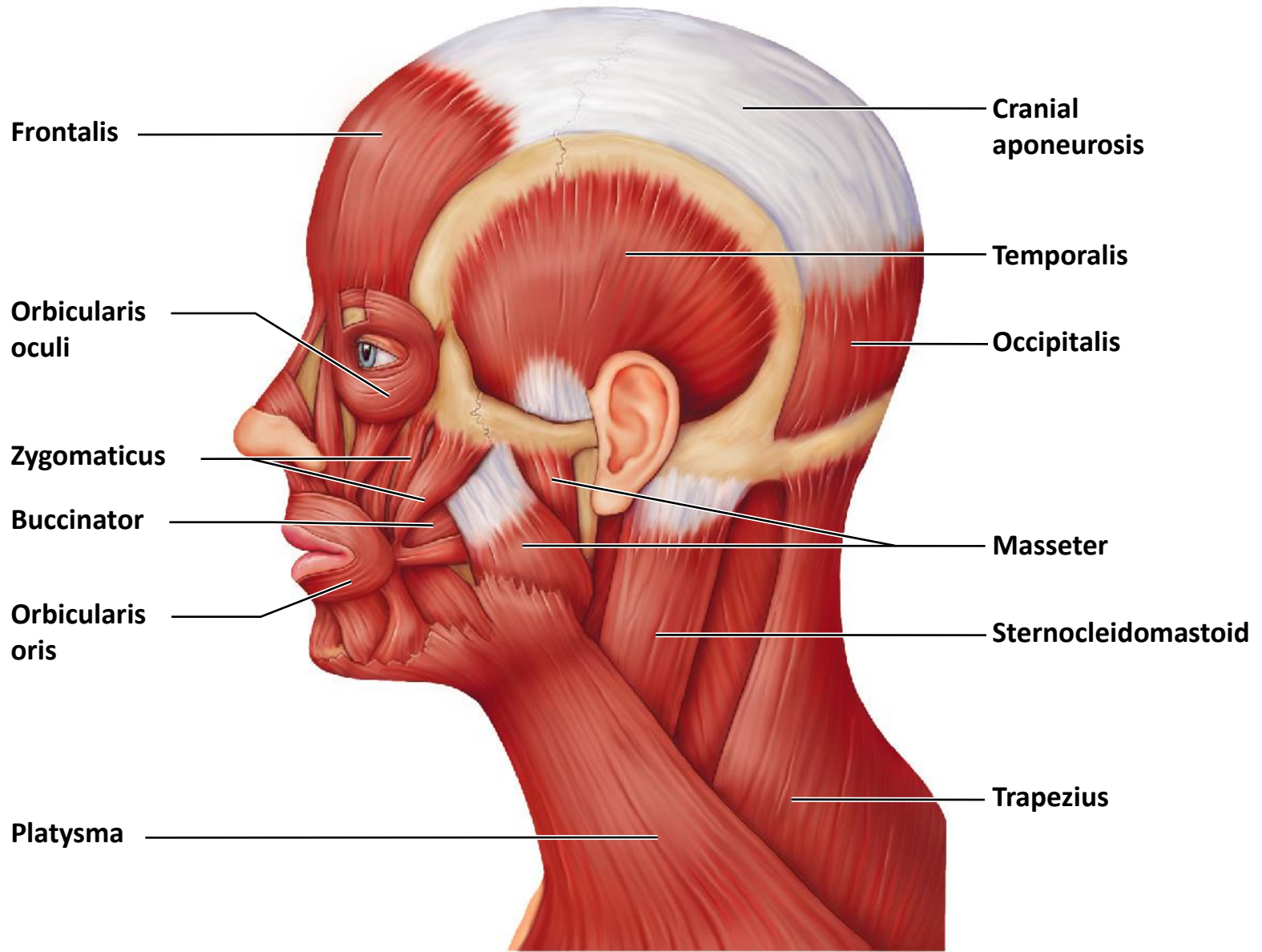


Figure 6.16a Muscles of the anterior trunk, shoulder, and arm. (a) Muscles crossing the shoulder joint, causing movements of the arm.

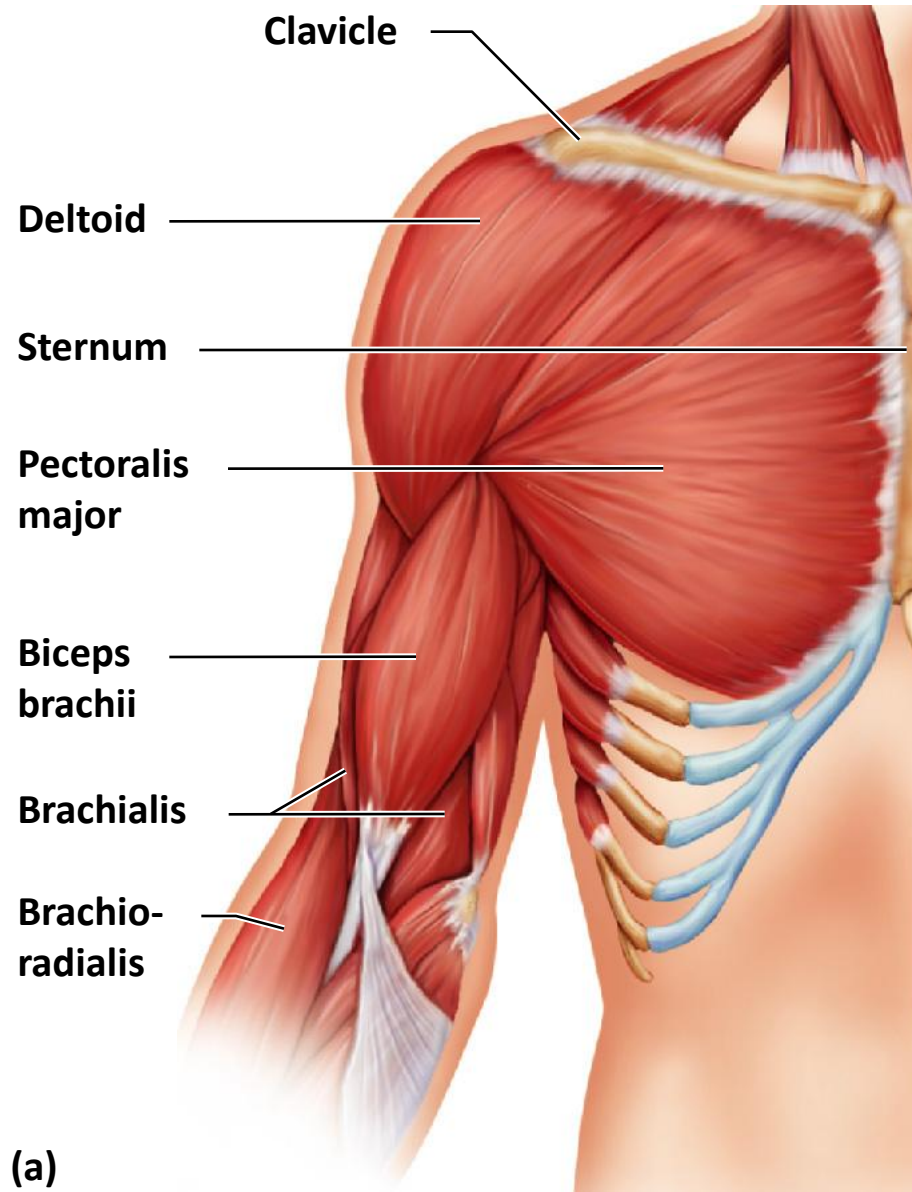
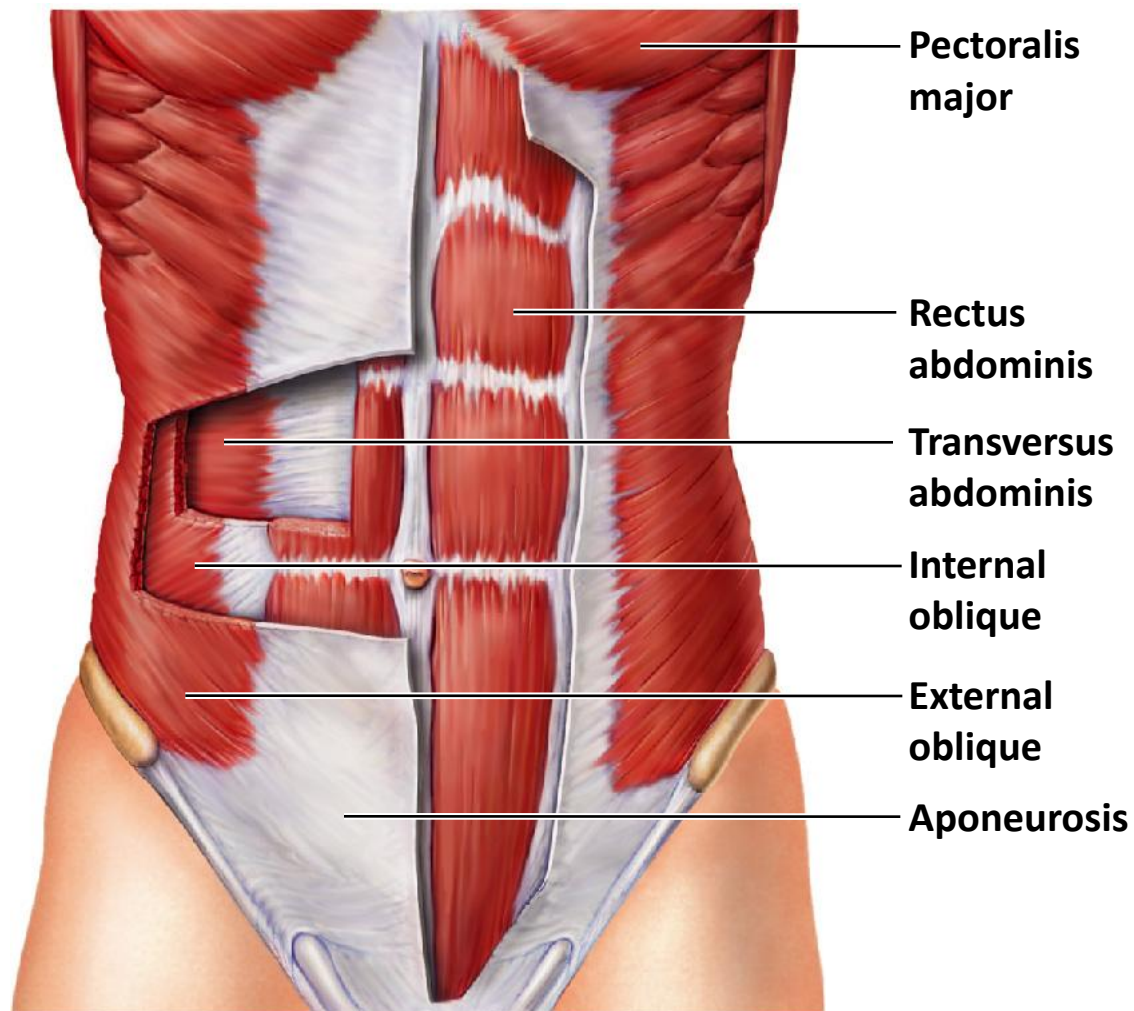


Figure 6.16b Muscles of the anterior trunk, shoulder, and arm. (b) Muscles of the abdominal wall.



(b)

Figure 6.17a Muscles of the posterior neck, trunk, and arm. (a) Superficial muscles.

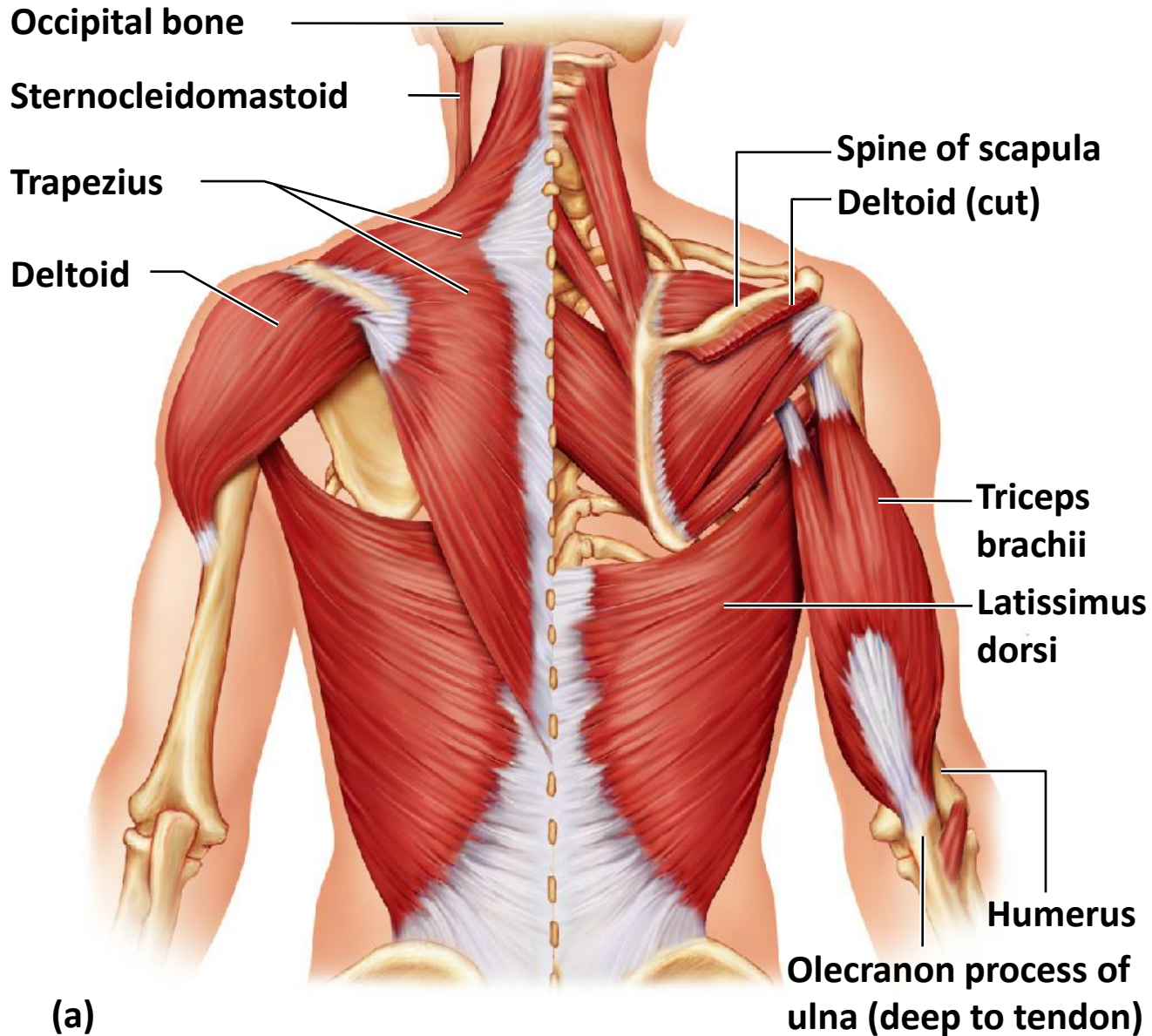


Figure 6.17b Muscles of the posterior neck, trunk, and arm. (b) The erector spinae muscles (longissimus, iliocostalis, and spinalis), deep muscles of the back.

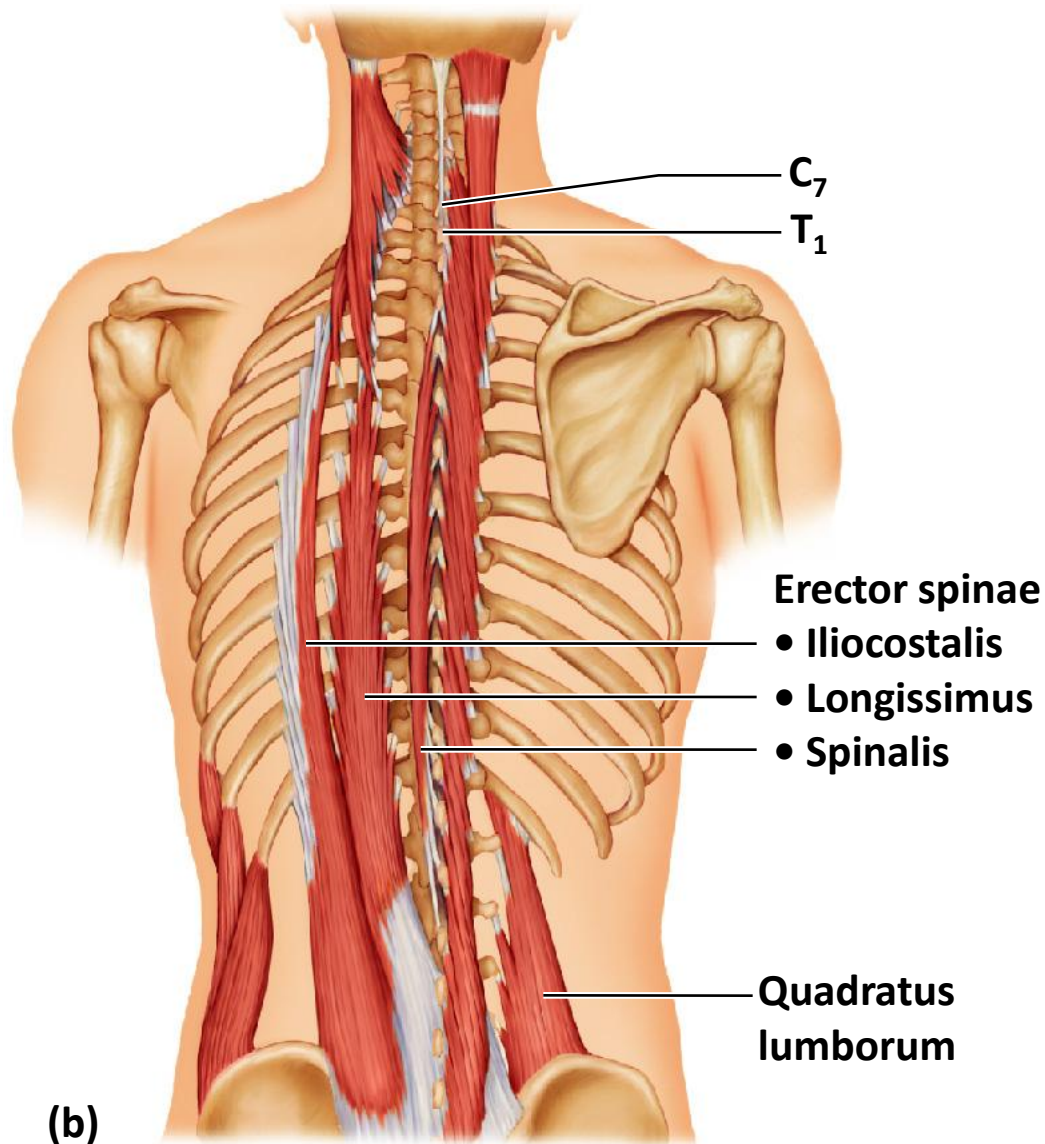


Figure 6.19a Pelvic, hip, and thigh muscles of the right side of the body. (a) Posterior view of the hip and thigh muscles.

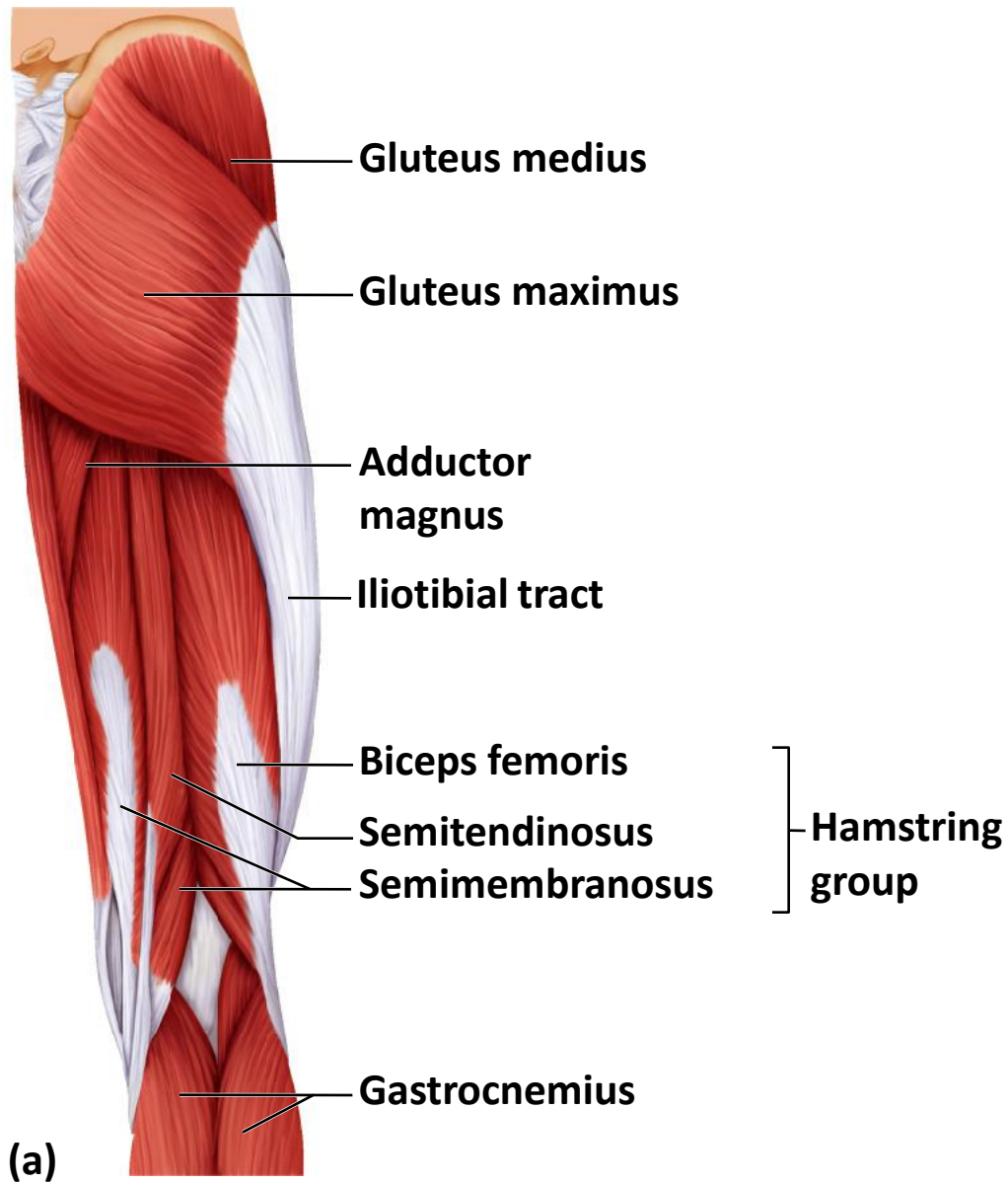


Figure 6.19c Pelvic, hip, and thigh muscles of the right side of the body. (c) Anterior view of pelvic and thigh muscles.

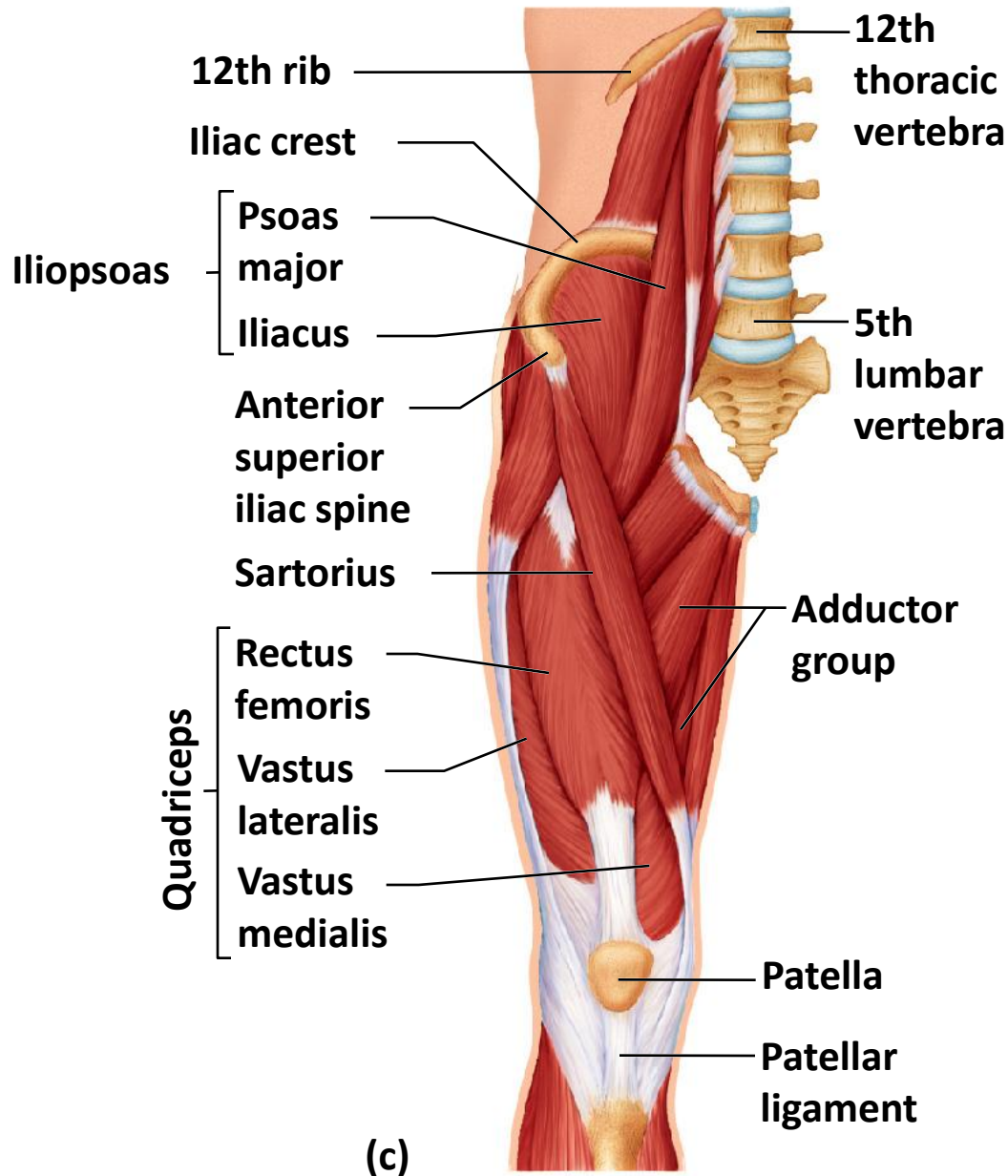


Figure 6.20a Superficial muscles of the right leg. (a) Anterior view.

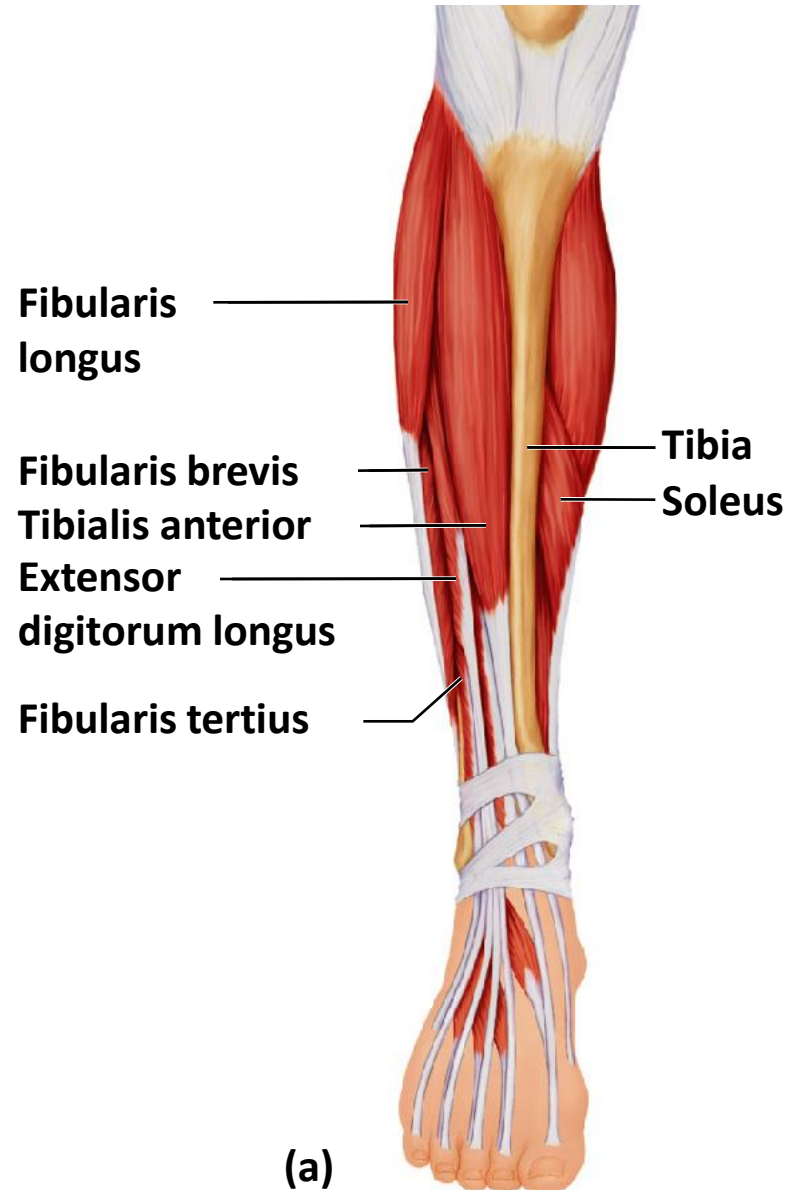


Figure 6.20b Superficial muscles of the right leg. (b) Posterior view.

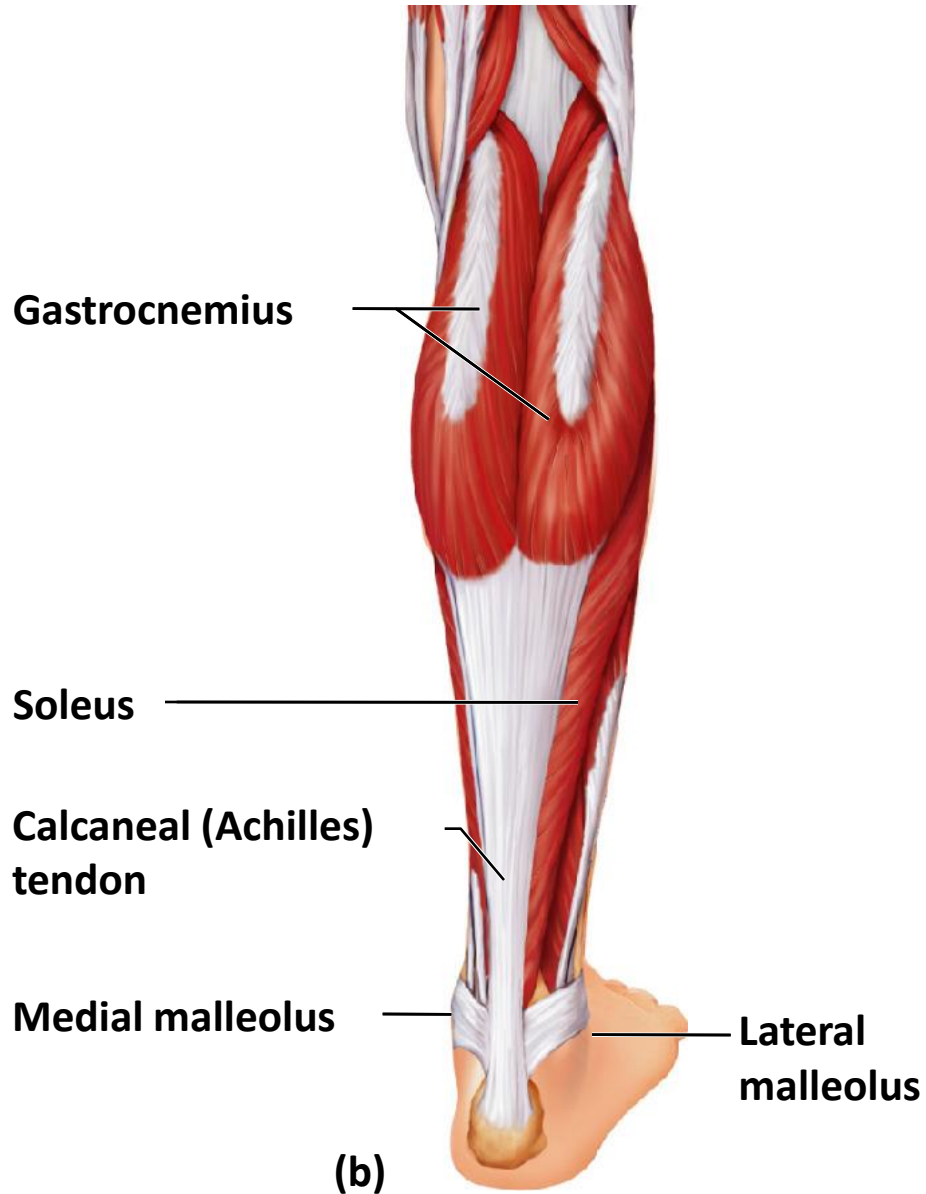


Figure 6.21 Major superficial muscles of the anterior surface of the body.

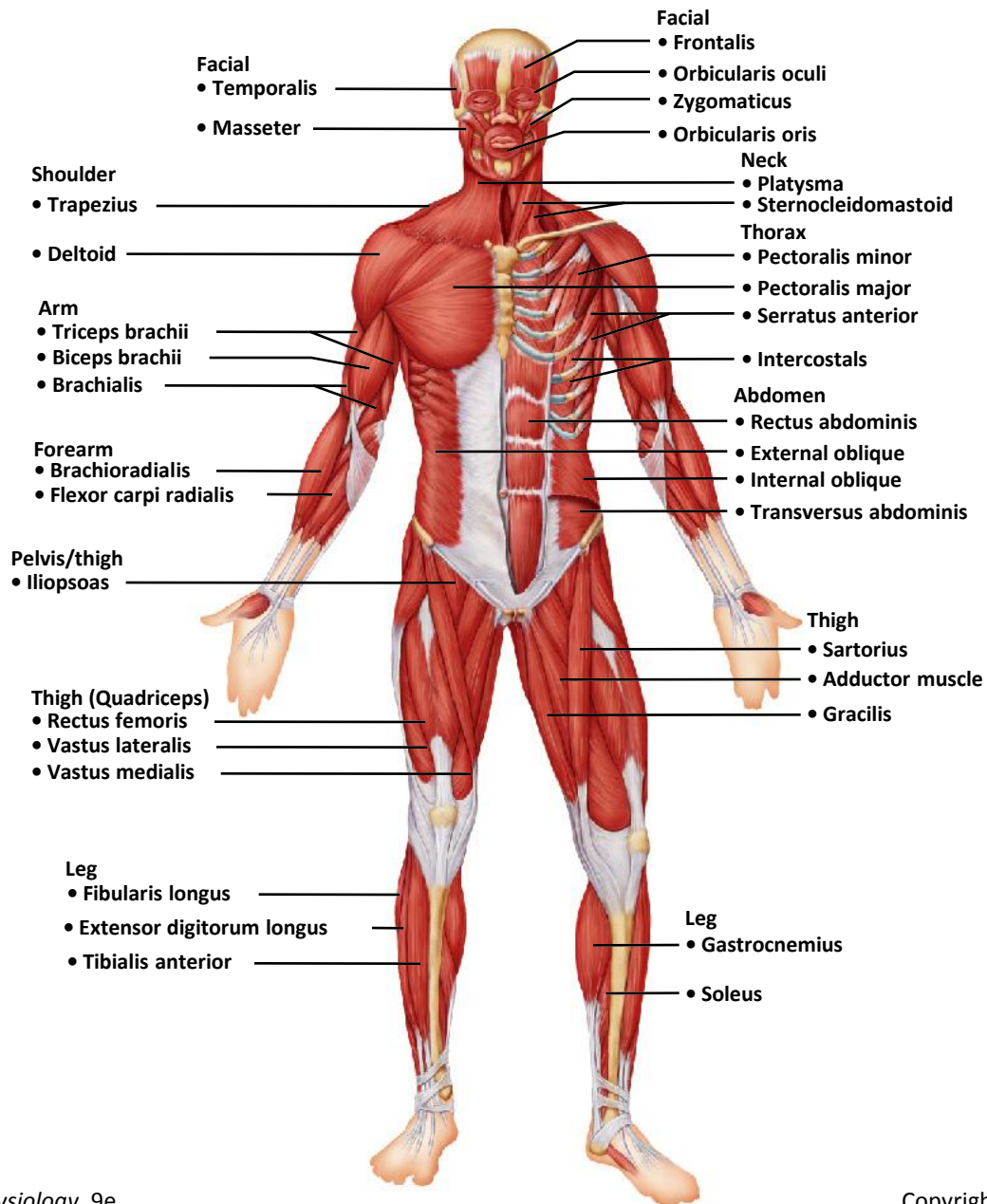


Figure 6.22 Major superficial muscles of the posterior surface of the body.

